

Jaw Muscles of Old World Squirrels

RICHARD W. THORINGTON, JR., AND KAROLYN DARROW
*Department of Vertebrate Zoology, Smithsonian Institution,
 Washington, D.C. 20560*

ABSTRACT The jaw, suprahyoid, and extrinsic tongue muscles were studied in 11 genera, belonging to five tribes, of Old World squirrels. Significant variation in most of the adductor muscles is evident. The most primitive state of sciuromorphy is seen in the African tree squirrels *Paraxerus* and *Funisciurus*, especially as reflected in the anterior deep masseter. A derived state of sciuromorphy is found in five genera of Old World squirrels and perhaps evolved independently in each. Reduction of the temporalis muscle was observed in three genera, distantly related to one another. A unique arrangement of the superficial masseter is reported in the Asian giant tree squirrels, *Ratufa*. The arrangement of the masseter in the African pygmy squirrel, *Myosciurus*, is very similar to that of the South American pygmy squirrel, *Sciurillus*. We present hypotheses about the functional significance of these differences. In the derived state of sciuromorphy, which is found in three cases in squirrels that feed extensively on hard fruits, the anterior deep masseter is well positioned to increase the strength of the power stroke of the incisor bite. Among the pygmy squirrels, the position of the anterior deep masseter suggests that it plays a more significant role in molar chewing. © 1996 Wiley-Liss, Inc.*

The jaw musculature of rodents has been the subject of study and basis for taxonomic classification for more than 150 years. Brandt (1855) divided the rodents into three groups based upon their masseter musculature and the basic attributes of this classification are to be found in the review by Simpson ('45). One of these groups, the Sciuromorphs, is characterized by the position of the origin of the anterior deep masseter muscle on the anterior surface of the zygomatic plate. Sciuromorphy evolved several times among the rodents, however, perhaps last among the squirrels themselves (Emry and Thorington, '82). Therefore, this morphology is not an indicator of common ancestry of all sciuromorphic rodents.

In the earliest known fossil squirrel, *Douglasia jeffersoni* (formerly *Protosciurus cf. jeffersoni*, Emry and Korth, '96), of the late Eocene, 35 mybp, the jaw musculature was protrogomorphous (Emry and Thorington, '82). It is likely that sciuromorphy evolved in the Sciuridae during the early Oligocene. In the earliest European fossil squirrels, *Palaeosciurus goti* and *Palaeosciurus feignouxi*, of the middle Oligocene, approximately 30 mybp, sciuromorphy was already evident (Vianey-Liaud, '74). In *Protosciurus mengi* of

the North American Miocene, the anterior deep masseter had moved forward onto the zygomatic plate, showing the initial stages of sciuromorphy (Korth, '87; Emry and Korth, '96).

Among recent squirrels, features of cranial morphology associated with the jaw musculature have played a significant role in subfamilial classification (Moore, '59). This musculature is well described for New World and Holarctic squirrels (Toldt, '05; Bryant, '45; Turnbull, '70; Ball and Roth, '95) but is practically unknown for tropical Old World squirrels (Parsons, 1894). It is clear from cranial morphology that jaw musculature varies among the Old World genera, and it appears as if various stages of sciuromorphy are represented among them. We document here the musculature associated with these stages of sciuromorphy and attempt to assess the evolutionary trends and functional changes they seem to represent. Additionally, it is possible that these stages provide clues about the times of divergence of the tribes of squirrels.

The function of jaw muscles has been well studied in *Rattus* (Hiimeae, '71b; Weijs and Dantuma, '75). In general, the jaw muscles of squirrels function similarly, although there

are clearly differences in details because of the differences in musculature. Squirrels lack the infraorbital portion of the masseter found in *Rattus* (Hiemae, '71a). Most squirrels have a comparatively more massive anterior deep masseter originating in front of the zygomatic plate. In other respects, the anatomy of the jaw muscles of squirrels and *Rattus* is similar. In both, there are two basic ways that the jaw functions, in molar chewing and in incisor biting. During the power stroke of chewing, the incisors do not occlude. The food is ground between the upper and lower molars with an upward and forward movement of the mandible under the maxilla, termed propalinal chewing. As in *Rattus*, the temporo-mandibular joint is probably unloaded (Hiemae, '71b; Weijs and Dantuma, '75). During the power stroke of biting, the mandible is protracted so that the incisors occlude and the molars do not. The mandibular incisors are forcefully raised against the maxillary incisors, and the temporo-mandibular joint is heavily loaded. Because of these similarities, the functions of the individual muscles of Old World squirrels are interpreted as being like those of *Rattus*, except when anatomical differences suggest otherwise. The objective is to provide hypotheses about the functional significance of the morphological differences we have observed.

We present descriptions of the jaw musculature of 12 genera of rodents. For reference to the primitive condition, protrogomorphy, in which the masseter muscle takes origin only from the zygomatic arch, we include *Aplodontia*, the mountain beaver of northern Oregon and Washington. We dissected all five genera of African tree squirrels, representing two tribes (Moore, '59). These are *Paraxerus*, a group of bush and tree squirrels found throughout much of sub-Saharan Africa, *Funisciurus*, a group of usually striped squirrels, and *Myosciurus*, the African pygmy squirrel (adults may weigh less than 20 g). All of these were included by Moore in the tribe Funambulini. The two other genera are *Heliosciurus*, the sun squirrels with an extensive range in sub-Saharan Africa, and *Protoxerus*, the African giant tree squirrel (weighing approximately 700 kg) which is more restricted to the high tropical forests. These genera belong to the tribe Protoxerini. Because specimens were not available, the only genus of African squirrels that we did not dissect was *Epixerus*, a primarily terrestrial member of the Protoxerini. We also included

in our study the Indian striped squirrel, *Funambulus*, which was considered by Moore ('59) to be closely related to the other Funambulini of Africa. Squirrels representing three additional tribes were also examined: *Callosciurus* and *Tamiops* are two genera of tree squirrels of the tribe Callosciurini which exhibits an extensive radiation of 13 genera in Southeast Asia; *Ratufa* is the genus of giant tree squirrels (some weighing in excess of 2 kg) found in India and Southeast Asia and represents the tribe Ratufini; *Xerus* and *Atlantoxerus*, of the tribe Xerini, are two genera of African ground squirrels. The 12 genera we dissected represent all the tribes of tropical Old World squirrels with the exception of the flying squirrels.

MATERIALS AND METHODS

Specimens dissected are listed in the appendix and their placement in Moore's ('59) classification of squirrels is listed in Table 1. Dissectable museum specimens of these genera are rare. Before undertaking this study we dissected specimens of *Sciurus carolinensis*, and compared them in detail with the

TABLE 1. Classification of the Sciuridae relevant to this study¹

Family Sciuridae
Subfamily Sciurinae
Tribe Ratufini: Indo-Malayan giant squirrels
<i>Ratufa</i> Gray, 1867
Tribe Protoxerini: African giant and sun squirrels
<i>Protoxerus</i> Major, 1893
<i>Epixerus</i> Thomas, 1909
<i>Heliosciurus</i> Trouessart, 1880
Tribe Funambulini: Indian and African tree and pygmy squirrels
Subtribe Funambulina: Indian striped squirrel
<i>Funambulus</i> Lesson, 1832
Subtribe Funisciurina
<i>Funisciurus</i> Trouessart, 1880
<i>Paraxerus</i> Major, 1893
Subtribe Myosciurina: African pygmy squirrel
<i>Myosciurus</i> Thomas, 1909
Tribe Callosciurini: Oriental squirrels
<i>Callosciurus</i> Gray, 1867
<i>Tamiops</i> Allen, 1901
<i>Sundasciurus</i> Moore, 1958
<i>Nannosciurus</i> Trouessart, 1880
<i>Dremomys</i> Heude, 1898
<i>Rhinosciurus</i> Gray, 1843
<i>Rubrisciurus</i> Ellerman, 1954
Tribe Sciurini: Holarctic and Neotropical tree and pygmy squirrels
<i>Sciurus</i> Linnaeus, 1758
Tribe Xerini
<i>Xerus</i> Hemprich and Ehrenberg, 1832. Ethiopian ground squirrel.
<i>Atlantoxerus</i> Major, 1893. Barbary ground squirrel.

¹Modified from Moore, '59.

morphology described by Ball and Roth ('95). In this and other recent studies (Thorington et al., '96a,b) we have examined the skulls of all genera of squirrels with the exception of *Rubisciurus*. During dissection, muscles were bisected between origin and insertion, and the mandible on one side was removed so that origins and insertions could be examined more carefully. We recorded our observations on camera lucida drawings made of the appropriate skulls and mandibles in the collections of the National Museum of Natural History.

Anatomical nomenclature remains a problem. The *Nomina Anatomica* ('66) for humans is inappropriate. The *Illustrated Veterinary Anatomical Nomenclature* (Schaller, '92) does not include rodents. Some terms normally used in comparative anatomy differ from both. We follow the terminology for muscles used by Ball and Roth ('95) to facilitate comparison.

The data presented in Table 2 are based on measurements of mandibles in the collection of the National Museum of Natural History. Measurements were taken from the middle of the mandibular condyle to the tip of the mandibular incisor, and to five other landmark points: the anteriormost point on the masseteric ridge, the retromolar space where the temporalis inserts behind the third molar, to the tip of the coronoid process, the anteroventral edge of the angular process, and the posterodorsal corner of the angular

process. Ratios were formed by dividing the first measurement into each of the others. These ratios estimate the mechanical advantage of the anterior and posterior deep masseter, the temporalis, the superficial masseter, and the medial pterygoid muscles.

RESULTS

Superficial masseter *Aplodontia rufa*

The origin is a flat wide tendon originating on the ventral portion of the zygomatic arch just ventral to the infraorbital foramen (Fig. 1). The tendon is folded over on itself along the ventral edge. Fibers insert on the medial corner of the angular process (Fig. 1), on its medial edge, and extensively on its dorsal surface, medial to the insertion of the medial pterygoid. There is no insertion on the homologue of the anterior deep masseter.

Paraxerus

The superficial masseter (Fig. 2) originates from the maxillary bone ventral and posterior to the infraorbital foramen via a flat wide tendon with a strong ventral fold. On skulls, the origin can be seen as a line extending from the anterior edge of the infraorbital foramen to a point dorsal and just anterior to the third premolar (Fig. 3a). Muscle fibers diverge from this tendon to insert onto the lateral and medial surfaces of the mandible. Some dorsal fibers insert on the posterior

TABLE 2. Ratios of mandibular measurements, lever arm/load arm (S.D.), for incisor bite¹

Species	(n)	Average length of load arm (S.D.)	A	B	C	D	E
<i>Aplodontia rufa</i>	(6)	52.9 (2.9)	.40 (.004)	.44 (.012)	.55 (.011)	.30 (.016)	.17 (.016)
African squirrels							
<i>Paraxerus palliatus</i>	(6)	33.9 (0.4)	.36 (.015)	.49 (.011)	.62 (.015)	.37 (.004)	.15 (.017)
<i>Funisciurus anaerythrus</i>	(8)	29.8 (1.4)	.30 (.010)	.47 (.026)	.60 (.011)	.35 (.014)	.14 (.016)
<i>Protoxerus stangeri</i>	(6)	48.2 (2.0)	.35 (.019)	.51 (.011)	.65 (.012)	.40 (.015)	.19 (.097)
<i>Heliosciurus rufobrachium</i>	(7)	33.7 (1.2)	.36 (.033)	.49 (.022)	.65 (.026)	.39 (.027)	.16 (.005)
<i>Heliosciurus gambianus</i>	(6)	30.6 (1.2)	.36 (.007)	.52 (.017)	.64 (.010)	.39 (.016)	.15 (.009)
<i>Myosciurus pumilio</i>	(5)	14.8 (0.3)	.35 (.015)	.45 (.018)	.72 (.025)	.41 (.026)	.30 (.009)
<i>Atlantoxerus getulus</i>	(6)	30.8 (0.9)	.34 (.022)	.47 (.021)	.63 (.010)	.38 (.010)	.19 (.013)
<i>Xerus erythropus</i>	(6)	38.2 (2.2)	.31 (.013)	.48 (.013)	.64 (.018)	.36 (.015)	.22 (.009)
Asian squirrels							
<i>Funambulus pennanti</i>	(6)	25.4 (0.9)	.34 (.017)	.46 (.024)	.67 (.012)	.40 (.019)	.26 (.016)
<i>Ratufa bicolor</i>	(6)	48.9 (2.1)	.38 (.019)	.54 (.010)	.67 (.010)	.38 (.008)	.18 (.024)
<i>Callosciurus notatus</i>	(6)	35.3 (0.2)	.33 (.008)	.45 (.011)	.63 (.010)	.38 (.010)	.21 (.015)
<i>Sundasciurus lowii</i>	(6)	27.5 (0.1)	.29 (.013)	.44 (.011)	.63 (.013)	.38 (.005)	.19 (.016)
<i>Sundasciurus hippurus</i>	(6)	42.8 (0.8)	.32 (.007)	.48 (.008)	.67 (.008)	.39 (.010)	.23 (.004)
<i>Tamiops macclellandi</i>	(6)	21.6 (0.6)	.33 (.017)	.46 (.005)	.63 (.009)	.39 (.016)	.18 (.023)
<i>Dremomys rufigenis</i>	(6)	35.7 (0.9)	.31 (.017)	.44 (.015)	.63 (.011)	.36 (.014)	.17 (.004)
<i>Rhinosciurus laticaudatus</i>	(6)	39.5 (1.4)	.27 (.011)	.34 (.012)	.54 (.016)	.33 (.008)	.24 (.015)

¹Load arm: condyle to tip of mandibular incisor; lever arm A: condyle to posterodorsal point of angular process; lever arm B: condyle to anteroventral point of angular process; lever arm C: condyle to anteriormost point of masseteric ridge; lever arm D: condyle to retromolar pit; lever arm E: condyle to tip of coronoid process.

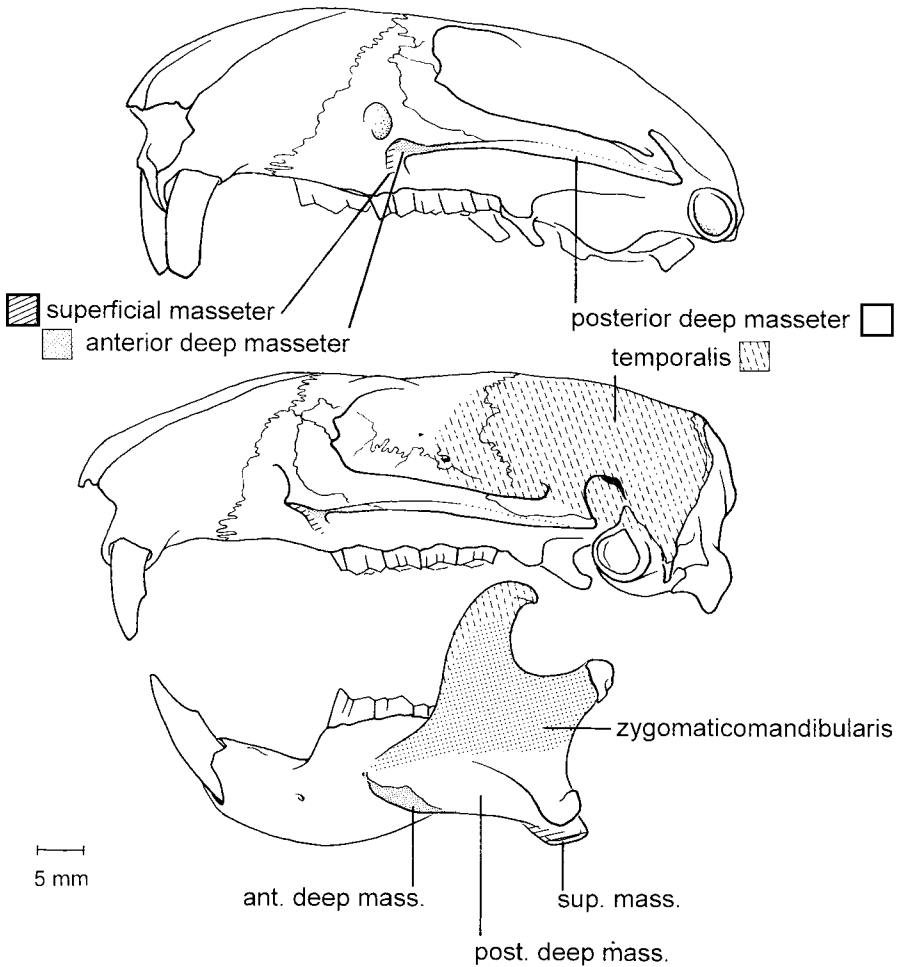
Aplodontia

Fig. 1. Origins and insertions of the jaw muscles of *Aplodontia rufa*.

portion of the tendon of insertion of the anterior deep masseter. The other dorsal fibers insert on the ventral and posterior edges of the angular process (Fig. 3a). The muscle fibers of the posterior deep masseter and those of the superficial masseter are not separable at this insertion. The more ventral fibers wrap around the ventral edge of the mandible and insert on the medial side of the angular process, ventral to the insertion of the medial pterygoid muscle (see Fig. 6). The dorsal edge of this insertion appears to be delimited by a ridge, separating it from the insertion of the medial pterygoid. This ridge is the point of insertion of the medial aponeurosis of the medial pterygoid. Some fibers of

the superficial masseter insert on this aponeurosis and others insert in the most anterior portion of the pterygoid fossa of the mandible.

Funisciurus

The muscle is similar to that of *Paraxerus* except in the following particulars. The origin is a flat wide tendon which is thicker at its ventral edge but not folded over on itself. In *Funisciurus anaerythrus* and *Funisciurus lemniscatus* fibers insert musculously both on the posterior edge of the angular process and on the tendon of insertion of the posterior deep masseter at the dorsal corner of the angular process. The superficial masseter of

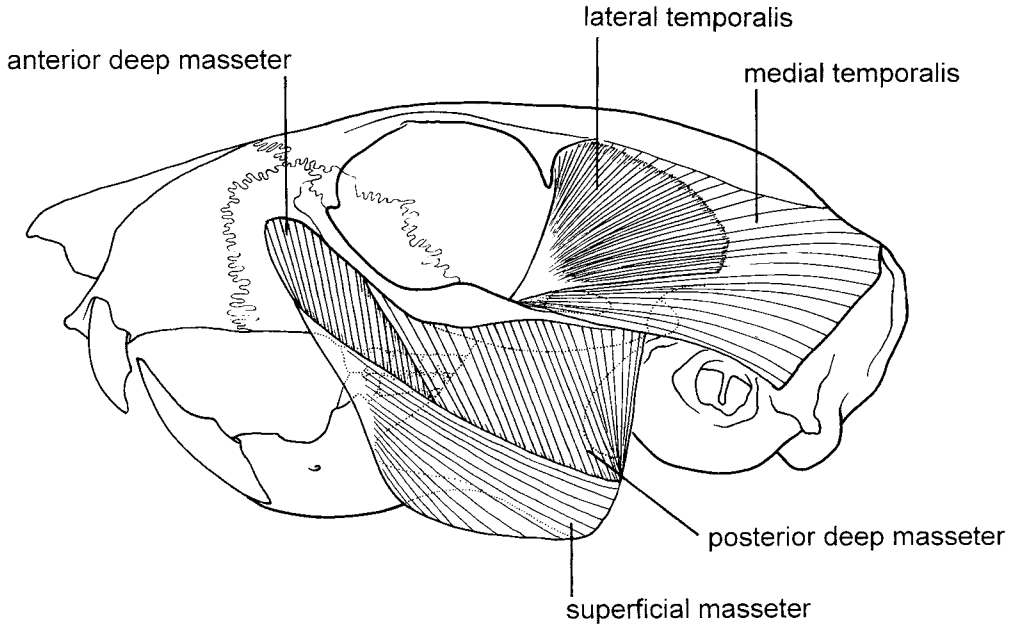


Fig. 2. Typical arrangement of the jaw muscles of squirrels, as seen in *Funisciurus pyrropus*.

Funisciurus pyrropus, by contrast, did not insert all the way to the dorsal corner of the angular process.

Myosciurus

The origin bears a different relationship to the infraorbital foramen because of the reduction of the infraorbital canal and the posterior location of the foramen in this species. The muscle originates from a small area near the ventral edge of the rostrum just caudal to the maxillary-premaxillary suture and well in front of the infraorbital foramen (Fig. 3a). The tendon of origin is a long, flat, wide ribbon that is not folded over on itself. On the lateral surface of the mandible, the muscle inserts on only the ventral edge of the angular process (Fig. 3a). On the medial surface of the mandible, it inserts extensively in a well-defined fossa ventral and anterior to the insertion of the medial pterygoid muscle.

Heliosciurus

The muscle is similar to *Paraxerus* except that the tendon of origin comes only from a protuberance, the masseteric knob, at the ventral edge of the infraorbital foramen (Fig. 3a). The tendon is more rope-like than ribbon-like, and the ventral edge is not folded over. In *Heliosciurus rufobrachium* the insertion

on the tendon of the anterior deep masseter is like that in *Paraxerus*. In *Heliosciurus gambianus* an insertion on this tendon is lacking.

Protoxerus

The muscle differs from *Paraxerus* in several respects. The tendon originates from a roughened area on the maxillary bone, ventral and anterior to the infraorbital foramen (Fig. 3a). This different position results from the retreat of the infraorbital foramen to the zygomatic plate and the absence of an infraorbital canal in *Protoxerus*. The tendon is folded over on itself on its ventral edge. Fibers of the superficial masseter insert extensively on the tendon of insertion of the anterior deep masseter, along the ventral masseteric ridge posterior to the insertion of the anterior deep masseter, and on the ventral half of the posterior edge of the angular process as well as on its medial surface (Fig. 3a). In *Protoxerus* the insertion of the superficial masseter is more closely associated with the anterior deep masseter than with the posterior deep masseter.

Funambulus

The muscle differs from that of *Paraxerus* in the following ways. The tendon

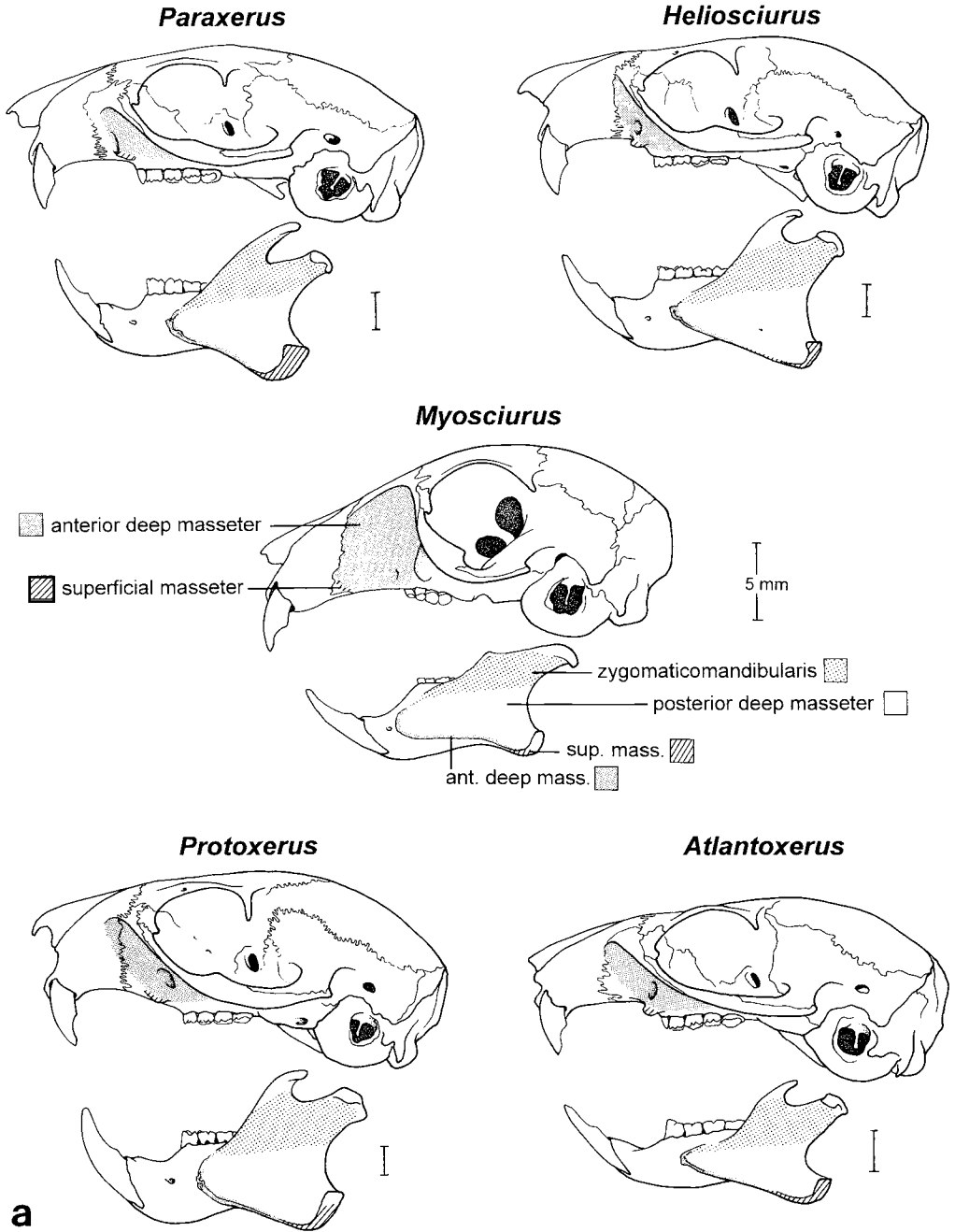


Fig. 3. Origins and insertions of the masseter muscles in (a) African squirrels and (b) Asian squirrels. Scale bars are all 5 mm.

of origin does not fold over on itself at the ventral edge, nor does it insert on the aponeurosis of the anterior deep masseter. At its insertion, the fibers of the super-

ficial masseter are separate from the fibers of the posterior deep masseter at the posterior edge of the angular process (Fig. 3b).

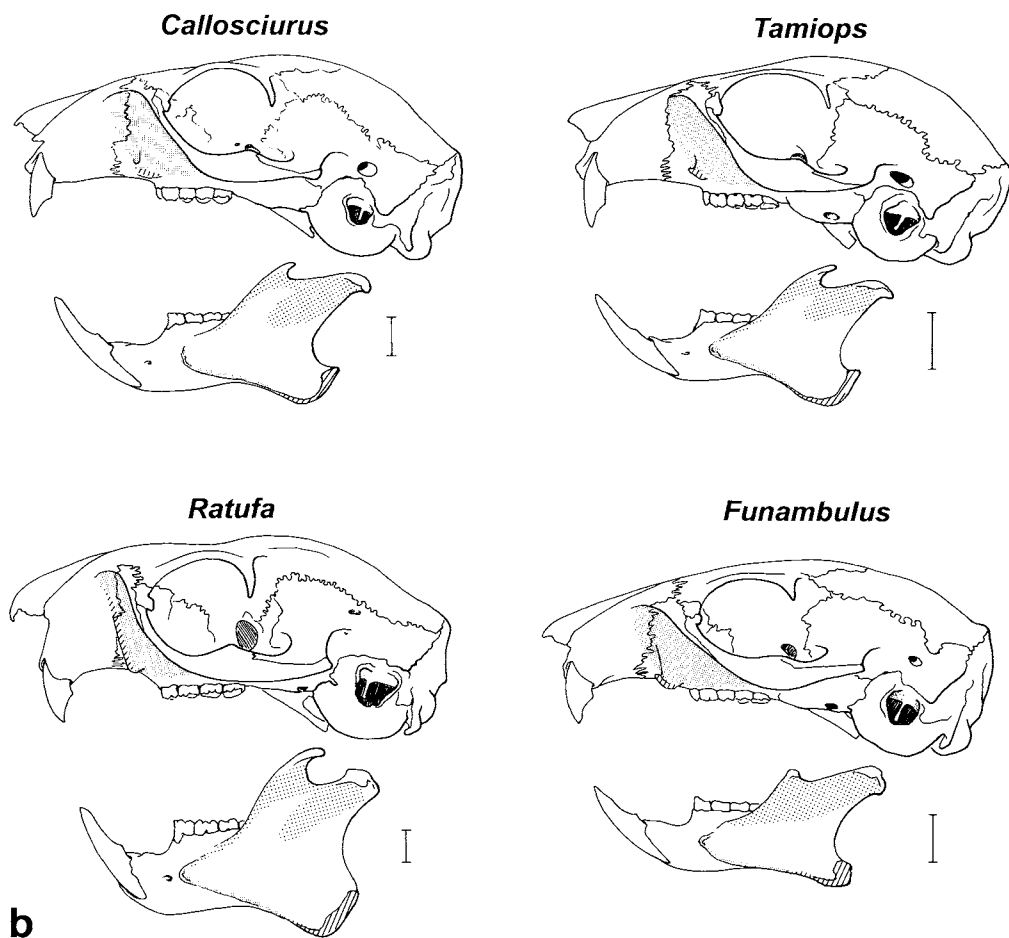


Figure 3 (Continued)

Callosciurus and *Tamiops*

The muscle differs from that of *Paraxerus* in that the tendon of origin lacks a ventral fold and muscle fibers do not insert onto the anterior deep masseter. In *Callosciurus* but not in *Tamiops*, fibers of insertion are extensively intermingled with fibers of the posterior deep masseter at their insertion onto the angular process. Further, some of the more dorsal muscle fibers of the superficial masseter insert deep to the fibers of the posterior deep masseter on the posterior edge of the angular process.

Xerus and *Atlantoxerus*

The muscle differs from that in *Paraxerus* in that the tendon originates from a masseteric knob, as in *Heliosciurus* (Fig. 3a), and the muscle does not insert onto the anterior

deep masseter. As in *Paraxerus*, but not *Heliosciurus*, the tendon of origin is folded over on itself at its ventral edge.

Ratufa

The superficial masseter is very different in this genus. The tendon of origin is very broad and extends from the ventral edge of the infraorbital foramen to the dorsal edge of the zygomatic plate (Fig. 3b). It has a thick ventral fold. The muscle fibers are not separable from those of the anterior deep masseter. The superficial fibers attributable to the superficial masseter insert in the usual pattern on the posterior edge and medial side of the angular process. Fibers of insertion of the superficial masseter are not separable from those of the posterior deep masseter.

*Anterior deep masseter**Aplodontia rufa*

The most anterior fibers of the lateral layer of the masseter are partially separable into a bundle that appears to be the homologue of the anterior deep masseter. These fibers originate from a pit on the ventral surface of the zygomatic arch, ventral and slightly lateral to the infraorbital foramen and just posterior to the origin of the tendon of the superficial masseter (Fig. 1). Some fibers originate from the deep side of the aponeurosis of origin of the posterior deep masseter. The insertion of this "anterior deep masseter" is muscular on the lateral surface of the mandible and aponeurotic on a ridge which appears to be the homologue of the ventral masseteric ridge on the mandible of squirrels. Posteriorly, the insertion of this muscle is inseparable from the insertion of fibers that originate more posteriorly on the zygomatic arch and that would appear to be homologous to the fibers of the posterior deep masseter of squirrels.

Paraxerus and Funisciurus

The anterior deep masseter (Fig. 2) originates from the zygomatic plate on the anterior surface of the zygoma and from the lateral surface of the maxillary bone (Fig. 3a), in front of the zygoma. This origin does not extend as high as the lacrimal bone and does not reach the premaxillary-maxillary suture. The muscle inserts aponeurotically along the ventral edge of the masseteric ridge (Fig. 3a). The aponeurosis does not extend to the dorsal portion of the masseteric ridge.

In *Funisciurus* and in *Paraxerus palliatus*, but not in *Paraxerus ochraceus*, there is a layer of muscle fibers originating from the deep surface of the medial aponeurosis of origin of the posterior deep masseter. This deep muscle layer is the posterior portion of the anterior deep masseter, as recognized by Ball and Roth ('95). The anterior fibers of this posterior portion are continuous with the fibers of the anterior portion of the anterior deep masseter, parallel it, and insert musculously on the lateral surface of the mandible and onto the ventral masseteric ridge posterior to the aponeurotic insertion of anterior deep masseter. The posterior fibers of this deep layer become progressively more parallel to the fibers of the posterior deep masseter and gradually become indistinguishable from it. This deep layer of muscle fibers inserts on the lateral surface of the mandible.

Myosciurus

The anterior deep masseter has an extensive origin from the zygomatic plate and from the whole surface of the maxillary bone on the lateral surface of the rostrum (Fig. 3a). The origin extends to, but not across, the maxillary-premaxillary suture. The fibers extend vertically and slightly posteriorly to insert on the ventral masseteric ridge and in a distinct fossa on the lateral surface of the mandible (Fig. 3a). The posterior portion of the anterior deep masseter muscle is a narrow, thin layer of fibers originating from the ventral edge of the zygomatic arch, deep to the posterior deep masseter. It inserts on the lateral surface of the mandible, posterior to the fibers originating from the zygomatic plate.

Heliosciurus

On the zygomatic plate and the side of the rostrum, the origin extends further dorsally and more anteriorly than in *Paraxerus* and in *Funisciurus*. The dorsal edge is at the level of the lacrimal bone and the anteriormost fibers take origin from the vicinity of the premaxillary-maxillary suture on the side of the rostrum (Fig. 3a). The insertion in *Heliosciurus* is restricted to the ventral portion of the masseteric ridge of the mandible (Fig. 3a). The insertion on the masseteric ridge is exclusively aponeurotic. The posterior portion of the anterior deep masseter is a layer of musculature on the deep surface of the aponeurosis of origin of the posterior deep masseter, similar to that seen in *Paraxerus palliatus*.

Protoxerus

The origin extends further to the side of the rostrum than in *Heliosciurus*, with the most anterior fibers taking origin from the premaxillary bone (Fig. 3a). The dorsal edge of the origin is at the level of the lacrimal bone. The muscle inserts aponeurotically on the ventral masseteric ridge and for a short distance on the dorsal masseteric ridge, but not as far as the base of the coronoid process (Fig. 3a). There is an extensive, thick posterior portion of the anterior deep masseter, originating from the deep surface of the medial aponeurosis of the posterior deep masseter (Fig. 4), as in *Paraxerus*. The medial aponeurosis is thicker and more extensive than that of *Paraxerus* and maintains the distinction between the muscle layers.

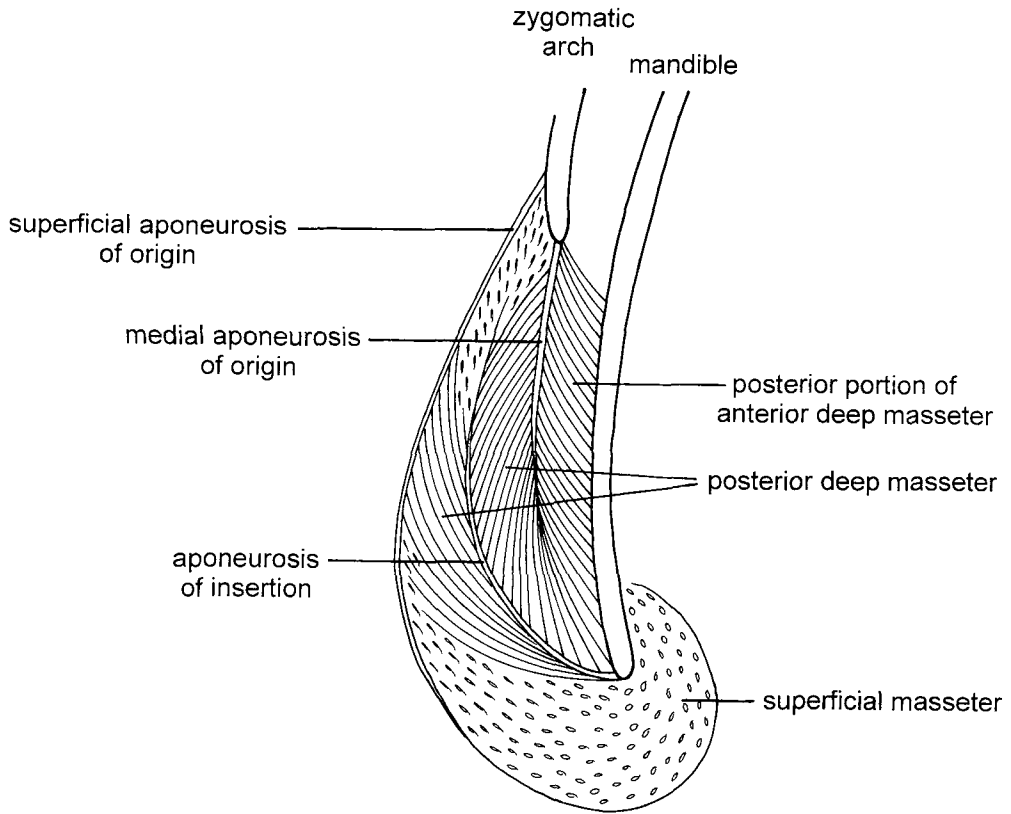


Fig. 4. Vertical cross-section of the masseter muscles as seen in *Protoxerus stangeri*. The section lies slightly posterior to M3.

We did not have specimens of *Epixerus* to dissect but we examined skulls. The deep fossa on the zygomatic plate and the prominence of the masseteric ridge suggest that *Epixerus* has an anterior deep masseter that is more massive and inserts more strongly on the mandible than it does in *Protoxerus*. The anterior deep masseter of *Rheithrosciurus*, a large terrestrial squirrel in Borneo, must be more remarkable yet, judging from the extraordinarily deep fossa on the side of the rostrum and the prominence of the masseteric ridges.

Funambulus

The origin extends to the side of the rostrum, anterior to the premaxillary-maxillary suture and dorsally as high as the lacrimal bone. The muscle inserts aponeurotically on the ventral masseteric ridge and on the dorsal masseteric ridge half way to the base of the coronoid process (Fig. 3b). The posterior

portion of the anterior deep masseter is a thin layer of muscle fibers originating from the deep surface of the medial aponeurosis of the posterior deep masseter. The aponeurosis does not extend the entire length of the zygomatic arch and the deep muscle layer tapers off toward its posterior end.

Callosciurus and *Tamiops*

In *Callosciurus* there is extensive origin from the side of the rostrum anterior to the premaxillary-maxillary suture. In *Tamiops* the origin extends only slightly beyond the premaxillary-maxillary suture. In both, the insertion on the mandible is almost exclusively aponeurotic on the ventral edge of the masseteric ridge (Fig. 3b). The insertion does not extend to the dorsal masseteric ridge. The posterior portion of the anterior deep masseter is an extensive layer of muscle fibers originating from the deep surface of the medial aponeurosis of the posterior deep mas-

seter. It inserts on the lateral surface of the mandible dorsal to the ventral masseteric ridge.

Xerus and *Atlantoxerus*

The origin extends as far dorsal as the lacrimal bone and anterior to the premaxillary-maxillary suture. It extends slightly beyond the suture in *Atlantoxerus* and extensively anterior to the suture in *Xerus*. The zygomatic plate in both genera is concave with a strong lateral edge. The insertion of the anterior deep masseter is restricted to the ventral edge of the masseteric ridge (Fig. 3a). There is a thin posterior portion of anterior deep masseter which takes origin from the medial aponeurosis of the posterior deep masseter and inserts on the lateral surface of the mandible and on the ventral masseteric ridge.

Ratufa

The origin extends dorsal to the lacrimal bone and anterior to the maxillary-premaxillary suture (Fig. 3b). The fibers are not separable from those of the superficial masseter. Fibers originating on the zygomatic plate insert aponeurotically on the ventral masseteric ridge and musculously on the lateral surface of the mandible. The posterior portion of the anterior deep masseter is a thin layer of muscle fibers originating from the deep aponeurosis of the posterior deep masseter, paralleling the fibers of the anterior fibers of the same muscle. The posterior portion inserts on the lateral surface of the mandible and on the ventral masseteric ridge.

Posterior deep masseter

Aplodontia rufa

This muscle originates from the ventrolateral surface of the zygomatic arch (Fig. 1) and from a thick aponeurosis which forms its deep surface. It inserts musculously on the whole ventral surface of the angular process except for its medial corner, posterior to the insertion of the anterior deep masseter and ventral to the insertion of the zygomaticomandibularis (Fig. 1). A tendon of insertion is lacking. A line of separation between the insertions of the posterior deep masseter and zygomaticomandibularis can be seen on the mandible. At their insertion, there is a very slight mingling of the dorsal fibers of the superficial masseter and the adjoining fibers of the posterior deep masseter.

Paraxerus and *Funisciurus*

The posterior deep masseter (Fig. 2) originates from the lateral surface of the zygomatic arch, the superficial aponeurosis, and the medial aponeurosis arising from the ventral edge of the zygomatic arch (Fig. 4). The medial aponeurosis is robust anteriorly and thinner toward the posterior end of the zygomatic arch. Where the medial aponeurosis ends, ventrally and posteriorly, separate layers of the anterior and posterior deep masseters are indistinguishable. The insertion of the posterior deep masseter is both aponeurotic and musculous. The aponeurosis of insertion extends from the dorsal corner of the angular process, ventrally along the insertion of the superficial masseter, and anteriorly along the ventral masseteric ridge. The musculous insertion is dorsal to the aponeurotic insertion and covers a broad area on the lateral surface of the angular process.

Myosciurus

The zygomatic arch is short in this species so the posterior deep masseter is narrow. It takes origin from the zygomatic arch and inserts tendinously on the posterior angle of the angular process and musculously for several millimeters more ventrally on the angular process.

Heliosciurus

The muscle is similar to that in *Paraxerus*. In *Heliosciurus rufobrachium* there is a distinct tendinous insertion on the posterior corner of the angular process and the groove adjoining the insertion of the superficial masseter. In *Heliosciurus gambianus* the insertion is tendinous only on the posterior corner of the angular process.

Protoxerus

The muscle is similar to that in *Paraxerus*, with a distinct aponeurotic insertion on the posterior corner of the angular process and in the groove that extends ventrally along the anterior edge of the insertion of the superficial masseter. The aponeuroses of origin and insertion are stronger and more extensive than in *Paraxerus* (Fig. 4).

Funambulur

The muscle is similar to that in *Paraxerus*, with a distinct tendinous insertion on the posterior corner of the angular process but with a musculous insertion more ventrally.

Callosciurus and *Tamiops*

The muscle is similar to that in *Paraxerus*, with a distinct tendinous insertion on the posterior corner of the angular process, but an aponeurotic insertion into the groove is lacking. In *Callosciurus* the insertion is more extensive, and for a short distance on the angular process some fibers of posterior deep masseter lie superficial to the fibers of the superficial masseter.

Xerus and *Atlantoxerus*

In these genera the zygomatic arch is twisted so that the origin of the posterior deep masseter is directed more ventrally than in the other genera described here. Short fibers take origin from the arch, the superficial aponeurosis, and the medial aponeurosis. These fibers insert on an extensive aponeurosis which inserts on the angular process and in the groove, as in *Protoxerus*.

Ratufa

The muscle is similar to that in *Protoxerus*.

*Zygomatocmandibularis**Aplodontia rufa*

The muscle originates from the medial surface of the zygomatic arch. There is a continuous line of musclicular insertion on the mandible (Fig. 1), dorsal to the insertions of the anterior and posterior deep masseters, as also illustrated by Tullberg (1899).

Paraxerus and *Funisciurus*

The anterior portion of the muscle originates from the orbital surface of the maxillary bone, lateral to the infraorbital canal, from the medial surface of the zygomatic arch, and from the dorsal surface of the zygomatic process of the squamosal (Fig. 5). The muscle inserts tendinously on the dorsal masseteric ridge and musculously on the lateral surface of the coronoid process (Fig. 3a). The insertion on the coronoid process extends along the anterior edge, in some specimens to the tip of the process, in others slightly ventral to the tip. The most dorsal fibers of the zygomatocmandibularis run immediately adjacent to the most ventral fibers of the medial temporalis, and in some specimens the two appear to be a continuous sheet of muscle. The tendon that inserts on the dorsal masseteric ridge forms on the deep side of the muscle and is overlain laterally by a thin layer of muscle fibers that insert on it. The posterior portion of the zygomatocmandibu-

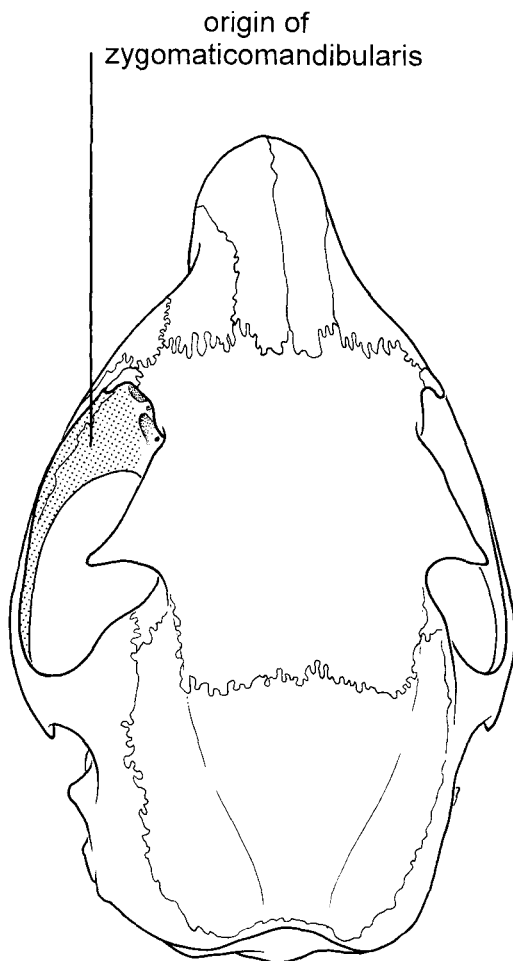


Fig. 5. Origin of zygomatocmandibularis as seen in *Paraxerus palliatus*.

laris originates from a fossa on the medial surface of the posterior portion of the jugal bone. It inserts into a fossa on the lateral surface of the condyloid process.

Myosciurus

The anterior portion has an extensive origin from the orbital surface of the zygomatic plate. The muscle inserts on the dorsal masseteric ridge posterior to the insertion of the anterior deep masseter and on the lateral surface of the mandible (Fig. 3a).

Heliosciurus

In *Heliosciurus rufobrachium* the origin and insertion of the muscle are as in *Paraxerus* (Fig. 3a). In *Heliosciurus gambi-*

anus the anterior portion inserts musc-
lously into a depression posterior to the an-
terior angle of the masseteric ridge, along the
dorsal masseteric ridge and along the an-
terior edge of the coronoid process but not
extending to the tip.

Protoxerus

The anterior portion of this muscle origi-
nates extensively from the orbital surface of
the zygomatic plate lateral to the infraorbital
foramen and from the medial surface of the
zygomatic arch. It inserts on the dorsal mas-
seteric ridge posterior to the insertion of an-
terior deep masseter (ventral to the posterior
edge of M_1) (Fig. 3a). The insertion is tendi-
nous along the dorsal masseteric ridge, but it
has an extensive muscous insertion on the
lateral surface of the coronoid process. The
posterior portion of the zygomaticomandib-
ularis is like that of *Paraxerus*.

Funambululus

The origin of the zygomaticomandibularis
is similar to that of *Paraxerus*, and its inser-
tion similar to that in *Protoxerus* (Fig. 3b).

Callosciurus and *Tamiops*

The origin is similar to that in *Paraxerus*.
The insertion of the anterior portion of this
muscle in *Tamiops* and some *Callosciurus*
extends from the anteroventral corner of the
masseteric ridge to the base of the coronoid
process (Fig. 3b). In some specimens of both
Callosciurus notatus and *Callosciurus fla-
vimanus* the insertion is slightly shorter and
there is a space between the insertions of the
anterior deep masseter and zygomaticoman-
dibularis. The muscle inserts by an aponeuro-
sis on its deep surface, with a thin layer of
fibers on the lateral surface inserting muscu-
lously along the dorsal masseteric ridge. The
insertion on the coronoid process is narrow
relative to that in *Paraxerus*. The posterior
portion inserts as in *Paraxerus*.

Atlantoxerus

The origin and insertion of the zygomatico-
mandibularis are similar to those of
Paraxerus (Fig. 3a).

Ratufa

The origin and insertion of the zygomatico-
mandibularis are similar to those of
Paraxerus (Fig. 3b).

Temporalis

Aplodontia

The medial temporalis has an extensive
origin on the frontal, parietal, and squamosal
bones (Fig. 1). It is bordered medially by the
temporal line, posteriorly by the nuchal crest,
and extends to the posterior root of the zyg-
omatic arch and into the orbit medial to the
coronoid process of the mandible. It inserts
aponeurotically on the superior and anterior
edges of the coronoid process, and muscu-
lously on the medial and lateral surfaces of
the coronoid (Fig. 1).

The lateral temporalis is thick and exten-
sive, covering more than the anterior half of
the medial temporalis. It inserts muscu-
lously on the tendon of insertion of medial
temporalis and on the dorsal surface and
anterior edge of the coronoid process.

Paraxerus and *Funisciurus*

The medial temporalis originates muscu-
lously from the squamosal and parietal bones
on the side of the skull, ventral to the tempo-
ral ridge, anterior to the nuchal crest, and
dorsal to the auditory meatus (Fig. 2). Some
fibers originate from the dorsal surface of the
medial half of the zygomatic process of the
squamosal. The muscle inserts tendinously
and muscously on the anterior edge and
medial surface of the coronoid process. The
most anterior fibers are oriented vertically
and insert toward the base of the coronoid
process, whereas the more posterior fibers
are oriented obliquely and insert more dor-
sally. Fibers originating at the back of the
skull near the nuchal crest insert near and on
the tip of the coronoid process. The muscle is
thickest posteriorly among these fibers. Fi-
bers originating from the zygomatic process
of the squamosal insert on the lateral surface
of the tip of the coronoid process.

The lateral temporalis takes origin from a
layer of fascia originating on the temporal
ridge, posterior to the postorbital process. It
overlies the anterior third of the medial tem-
poralis and inserts tendinously on the tendon
of insertion of the medial temporalis near the
midpoint of the anterior edge of the coronoid
process.

Myosciurus

The temporalis is greatly reduced in this
species. It is a single muscle that originates
only from the squamosal bone on the lateral
surface of the skull. It inserts tendinously on

the tip of the reduced coronoid process and along the medial surface of its anterior edge.

Heliosciurus

The origins of both the medial and lateral temporalis are similar to those of *Paraxerus*. However, the lateral temporalis inserts musculously on the posterior portion of the aponeurosis of insertion of the medial temporalis beginning dorsal to the tip of the coronoid process and continuing along the anterior edge more than halfway to the base.

Protoxerus

Origin and insertion of the medial temporalis are similar to those of *Paraxerus*, with some fibers originating from the zygomatic process of the squamosal and inserting on the lateral surface of the coronoid process. However, the tendinous insertion of the medial temporalis on the lateral surface of the coronoid process is more extensive.

Lateral temporalis covers approximately half of the medial temporalis and inserts musculously on the medial temporalis, as in *Heliosciurus*.

Funambulus

The medial temporalis is similar to that of *Paraxerus* but it is thickest toward the middle of the muscle. It inserts tendinously on the much-reduced coronoid process with the majority of its fibers more vertically oriented than in *Paraxerus*.

The lateral temporalis is similar to that of *Paraxerus*, inserting tendinously near the midpoint of the anterior edge of the coronoid process.

Callosciurus and *Tamiops*

In *Callosciurus* the medial temporalis has a broad tendon which inserts on both the anterior and posterior edges of the coronoid process. In *Tamiops* a small tendon inserts only on the tip and anterior edge of the coronoid process.

The origin of the lateral temporalis is similar to that of *Paraxerus*. In *Tamiops* the muscle inserts tendinously behind the third molar. In *Callosciurus* the muscle inserts tendinously near the base of the coronoid process and behind the third molar.

Atlantoxerus

The origins of both the medial and lateral temporalis are similar to those of *Paraxerus*. The lateral temporalis inserts both muscu-

lously and aponeurotically on the medial temporalis, starting very close to the temporal line and extending slightly ventral to the tip of the coronoid process. The medial temporalis inserts aponeurotically on the tip and anterior edge, and musculously on the medial surface of the anterior edge of the coronoid process. In *Xerus* the posterior portion of the lateral temporalis is thinner and the coronoid process is smaller than that of *Atlantoxerus*.

Ratufa

The medial temporalis has an extensive origin on the frontal, parietal, and squamosal bones. It is bordered medially by the temporal line, posteriorly by the nuchal crest, and extends onto the zygomatic process of the squamosal and into the orbit medial to the coronoid process of the mandible.

Fibers of the lateral temporalis take origin from fascia attached to the temporal line. The muscle covers the anterior half of the medial temporalis and inserts musculously on its aponeurosis of insertion, starting just slightly ventral to the temporal line and extending halfway down the coronoid process.

Medial pterygoid

Aplodontia

The medial pterygoid originates on the ventral surface of the skull from the pterygoid fossa and ectopterygoid ridge as far posterior as the anterior edge of the auditory bulla. It inserts on the medial side of the mandible in the large pterygoid fossa of the angular process. The angular process in *Aplodontia* is deeply inflected so that the medial surface faces dorsally.

Paraxerus and *Funisciurus*

The origin of the medial pterygoid is similar to that of *Aplodontia* (Fig. 6). It inserts on the medial side of the mandible in the large pterygoid fossa of the angular process (Fig. 6), although this process has a very different orientation from that in *Aplodontia*. No significant variation in the medial pterygoid was noted among the squirrels. Different patterns of tendinous inscriptions within the muscle are reflected in ridges within the fossae of origin and insertion.

Lateral pterygoid

Aplodontia

The lateral pterygoid originates on the skull from the lateral pterygoid plate which lies

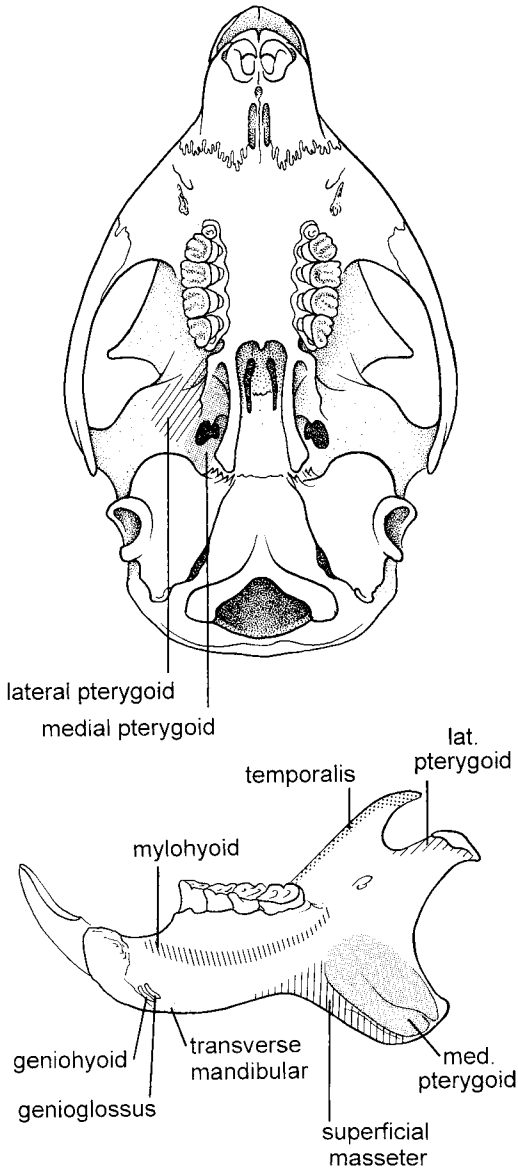


Fig. 6. Ventral view of the skull and medial view of the mandible of *Paraxerus palliatus*, showing origins and insertions of selected muscles.

posterior to the third molar. Its origin is extensive, lying lateral to the origin of the medial pterygoid and medial to the articulation with the mandibular condyle, and extending almost to the auditory tube. The lateral pterygoid inserts on the medial surface of the condylar process of the mandible, immediately proximal to the condyle itself.

Paraxerus and *Funisciurus*

The lateral pterygoid originates lateral to the lateral pterygoid ridge between the third molar and the auditory bulla (Fig. 6). Its origin is approximately as long as that of the medial pterygoid, but it is narrower and its origin extends only one third of the distance from the lateral pterygoid ridge to the articulation with the mandibular condyle. The muscle inserts on the medial surface of the condylar process of the mandible, immediately proximal to the condyle itself (Fig. 6). No significant variation of the lateral pterygoid was noted among the other squirrels.

Suprahyoid muscles

The suprahyoid muscles were examined in all genera and compared with the detailed descriptions given for *Sciurus carolinensis* by Ball and Roth ('95). These are very conservative muscles and vary only slightly among the genera.

Digastric

Aplodontia

The anterior digastric arises broadly from the ventral surface of the mandible at and posterior to the symphysis. It is a broad, thick muscle and the left and right digastric muscles are not separable. The posterior digastric originates by a broad tendon from the paroccipital region posterior to the auditory tube. The anterior and posterior bellies are joined, in the "sciurormorphine" manner, by a tendon that is firmly attached to the hyoid and to a tendinous arch of the hyoid (Hill, '37).

Paraxerus and *Funisciurus*

The anterior digastric arises by a tendon from the ventral surface of the mandible just posterior to the symphysis. The posterior digastric originates by a tendon from the paroccipital process. They are joined by a tendon that is firmly attached to the hyoid. The bellies of the right and left anterior digastric muscles are separable over their whole length in *Paraxerus*, and over the anterior half of the muscle in *Funisciurus*.

The only variation we have observed in the digastric among the squirrels is the degree of fusion of the right and left bellies of the anterior portion. In *Protoxerus* and *Ratufa* the bellies are separate only along the anterior half and are inseparable along their posterior half.

*Transverse mandibular**Aplodontia*

The transverse mandibular extends between the right and left mandibles deep to the origin of the digastric and is closely bound to it. Its origin is marked by a ridge on the ventral surface of the mandible, which extends to a point ventral to PM₄.

Paraxerus and Funisciurus

The transverse mandibular lies between the right and left mandibles deep to the digastric on the ventral edge of the mandible (Fig. 6). It extends from the posterior edge of the symphysis posteriorly to approximately a point directly ventral to the posterior edge of the diastema.

The muscle varies in thickness. It is rather thin in *Ratufa* and especially thick in *Protoxerus* and *Atlantoxerus*.

*Mylohyoid**Aplodontia*

The mylohyoid originates from the medial side of the mandible, ventral to the premolar and molar teeth, and extends a slight distance behind M₃. Fibers pass medially and slightly posteriorly. The anterior fibers join those from the opposite side in a median raphe, and the more posterior fibers insert on the hyoid.

Paraxerus and Funisciurus

The mylohyoid originates from the medial side of the mandible, ventral to the premolar and molar teeth, and extends a slight distance behind and around M₃ (Fig. 6). Fibers pass medially and slightly posteriorly. The anterior fibers join those from the opposite side in a median raphe, and the more posterior fibers insert on the hyoid. In *Ratufa* the origin is farther ventral to the molars and does not curve around behind M₃. No variation in this muscle was noted among the other squirrels.

*Geniohyoid**Aplodontia*

The geniohyoid originates from the medial surface of the mandible, just posterior to the symphysis and dorsal to the transverse mandibular muscle. The right and left geniohyoids pass posteriorly in close contact with the mylohyoid and insert on the hyoid.

Paraxerus and Funisciurus

The geniohyoid is very similar to that in *Aplodontia*. No variation in this muscle was noted among the squirrels.

*Stylohyoid**Aplodontia*

The stylohyoid originates from the paroccipital process and the adjoining surface of the bulla. It inserts on the hyoid.

Paraxerus and Funisciurus

The stylohyoid originates from the anteroventral surface of the paroccipital process and the adjoining surface of the bulla. It inserts on the hyoid, normally dorsal to the digastric tendon. In *Protoxerus* the muscle originates from the stylohyal on the lateral surface of the bulla and wraps around the posterior belly of digastric to insert on the ventral surface of the digastric tendon.

*Extrinsic tongue muscles**Genioglossus*

Aplodontia. The genioglossus originates from the medial surface of the mandible posterior to the symphysis and dorsal to the origin of the geniohyoid. It extends into the ventral surface of the tongue.

Paraxerus and Funisciurus. The genioglossus originates from the medial surface of the mandible posterior to the symphysis and dorsal to the origin of the geniohyoid (Fig. 6). It extends to the ventral surface of the tongue but a few fibers commonly insert on the hyoid as well. No variation was noted among the squirrels.

Hyoglossus

Paraxerus. The hyoglossus originates from the hyoid dorsal to the insertion of the mylohyoid and geniohyoid. It extends into the ventral surface of the tongue. The same morphology was observed in *Protoxerus* and *Ratufa*. This muscle was not studied in the other squirrels.

Styloglossus

Paraxerus. The styloglossus originates from the ventral surface of the auditory bulla and extends anteriorly and medially to the tongue. This muscle was not studied in the other genera.

DISCUSSION

The extraordinary ecological and evolutionary success of the rodents is attributed in

part to their adaptations for biting and chewing. This entails an emphasis of the masseter musculature, in contrast to the emphasis of the temporalis musculature of many other mammals (Turnbull, '70). In hystricomorphy and myomorphy, the deepest layer of the masseter muscle, the zygomaticomandibularis, migrates through the infraorbital foramen to the side of the rostrum. The evolution of sciuromorphy involves almost exclusively a more superficial layer of the masseter, the anterior deep masseter, which migrates in front of the zygomatic plate and onto the side of the rostrum. Stages in the course of this evolution can be seen in the fossil record (Black, '63; Vianey-Liaud, '74; Emry and Thorington, '82).

In contrast, the superficial masseter muscle is relatively conservative. In most squirrels it differs remarkably little in origin and insertion from that seen in the protrogomorphous *Aplodontia*. In *Aplodontia* the superficial masseter originates from the zygomatic arch, considerably lateral to and only slightly in front of PM₃. It does not originate from a tubercle. In the earliest fossil squirrels of the Eocene and Oligocene, *Douglassia jeffersoni*, *Palaeosciurus goti*, and *Palaeosciurus feignouxii*, the muscle originates from a tubercle on the side of the rostrum, slightly anterior to PM₃. In the modern African squirrels *Paraxerus* and *Funisciurus*, a small tubercle lies no further forward than in *Palaeosciurus goti*. However, in all of these animals the position of the origin of the muscle relative to the infraorbital foramen is the same: ventral and slightly posterior. In the xerines and in *Heliosciurus*, the tubercle is a prominent knob, unlike that in the fossil squirrels. Among the protoxerini, this morphology is seen only in *Heliosciurus*, not in the other two genera, *Protoxerus* and *Epixerus*. It is the only derived feature shared by *Heliosciurus* and the xerines, so we suspect it was probably independently derived in these two groups. In *Protoxerus* and in *Myosciurus* the superficial masseter does not originate from a tubercle, but the position of the origin relative to the toothrow is the same as in other squirrels. It is the infraorbital foramen that differs, as described previously. The origin of the superficial masseter differs greatly in *Ratufa*. Its morphology could be derived from that of other squirrels, but it is so different that we wonder if *Ratufa* evolved sciuromorphy independent of all other squirrels.

The insertion of the superficial masseter on the angular process varies little among squirrels and is basically the same as in *Aplodontia*. The angular process is commonly missing in fossils but for *Palaeosciurus goti* it is illustrated (Vianey-Liaud, '74) as being exactly like that of modern squirrels. The insertion of the superficial masseter on the anterior deep masseter, seen in *Paraxerus*, *Funisciurus*, and *Protoxerus*, appears to be a derived feature because it is absent in *Aplodontia* and diverse modern squirrels including *Xerus*, *Funambulus*, *Callosciurus*, and *Heliosciurus*. The most derived condition is that seen in *Protoxerus*. In most squirrels the superficial masseter inserts on the whole posterior edge of the angular process. In *Protoxerus*, *Myosciurus*, and *Funisciurus pyrropus* the insertion is restricted to the ventral half, or less, of the posterior edge of the process.

In *Rattus* the superficial masseter is active during the power strokes of both chewing and biting (Hiemae, '71b; Weijs and Dantuma, '75). During the power stroke of biting the superficial masseter acts with a lever arm that is determined by the depth of the mandible. The most dorsal fibers have a lever arm measured by the distance from the mandibular condyle to the dorsal corner of the angular process (Table 2, column A). The most ventral fibers have a lever arm measured by the distance from the mandibular condyle to the most anteroventral point of the process (Table 2, column B). These values are high, indicating the greatest mechanical advantage, in *Ratufa*, *Heliosciurus gambianus*, and *Protoxerus*. Among the African squirrels, *Protoxerus* and *Epixerus* are the most notable for feeding on hard nuts (Emmons, '80), and these are the genera with the most massive superficial masseter muscles and high ratios of lever arm to load arm. *Ratufa* also feed extensively on hard nuts (Payne, '80). In the power stroke of chewing, with the mandibular condyle unloaded, the length of the lever arm is irrelevant, and the fibers of the superficial masseter lie at an angle of approximately 30–40° to the occlusal plane of the molars. Under these conditions the superficial masseter will both close the jaw and pull the mandible forward during propalinal chewing.

The migration of the origin of the anterior deep masseter to the zygomatic plate is the principal feature of sciuromorphy. *Paraxerus* and *Funisciurus* appear to retain an early

stage of sciuromorphy, in which the origin of the muscle extends only part way up the anterior root of the zygomatic arch and lies well posterior to the premaxillary-maxillary suture. It is probable that the primitive nature of this feature in *Paraxerus* and *Funisciurus* documents an early divergence of this lineage from that of the other squirrels, perhaps in the early Miocene or during the Oligocene. A more advanced state is seen in *Heliosciurus*, *Atlantoxerus*, and *Tamiops*, in which the muscle extends to the premaxillary-maxillary suture or barely crosses it. In the other modern genera described above, the origin extends well across the suture and to the premaxillary bone. If the trend toward the derived state has been unidirectional, this migration of the insertion to the premaxillary bone may have evolved independently six times. The derived states of both *Ratufa* and *Xerus* are sufficiently different from other squirrels to suggest that they have each evolved independently. Among the Callosciurini, the derived condition is found in *Callosciurus* while the primitive condition is retained in the closely related *Tamiops*. Similarly, among the Protoxerini the derived condition is found in *Protoxerus* while a more primitive condition is found in *Heliosciurus*. If the evolutionary trend is not unidirectional, then the more primitive state may have been repeatedly re-derived in the closely related genera. The derived state may also have evolved independently in *Sciurus* and *Funambulus*, which are not closely related to each other.

The insertion of the fibers of the anterior deep masseter on the ventral masseteric ridge appears to be primitive in view of the similar morphology seen in *Aplodontia* and a wide variety of modern squirrels. Where the ridge is visible in fossil squirrels, it has the same appearance as in extant forms. The insertion of the muscle on the dorsal masseteric ridge, which is absent in *Aplodontia*, appears to be derived. It is impossible to confirm this polarity with fossil evidence because the insertions of the anterior deep masseter and the zygomaticomandibularis on the dorsal masseteric ridge are indistinguishable. The dorsal masseteric ridge is very prominent in the Eocene *Dougllassia*, but which muscle inserted on it is not known. Among modern squirrels the derived condition appears to have evolved independently in three distantly related genera: *Protoxerus*, *Funambulus*, and *Sciurus*.

In the African pygmy squirrel, *Myosciurus*, the muscle has an extensive origin from the rostrum, but the origin does not extend across the premaxillary-maxillary suture. The zygomatic plate is oriented much more vertically than in larger squirrels and the fibers of the muscle are also vertically oriented. The insertion is very far forward on the mandible and the aponeurotic insertion extends to the dorsal portion of the masseteric ridge. This is the same pattern of origin and insertion seen in the South American pygmy squirrel, *Sciurillus* (Ball and Roth, '95), and inferred from cranial morphology for the Asian pygmy squirrels, *Exilisciurus* and *Nannosciurus*. This morphology has evolved independently in the three different lineages of pygmy squirrels.

The anterior end of the masseteric ridge usually lies ventral to PM_4 or M_1 in recent squirrels. As noted by Emry and Thorington ('82), in paramyids of the Eocene, it is usually at least as far back as the posterior part of M_2 and in *Dougllassia* and *Protosciurus* of the Oligocene it was ventral to the posterior part of M_1 . In *Aplodontia* it also lies ventral to M_1 . The effect of the more anterior insertion of the anterior deep masseter is to increase the ratio of the moment arm of its insertion to the moment arm of the incisor bite, and thus to increase the strength of the incisor bite. This ratio is .548 in *Aplodontia*, and greater than .600 in most squirrels (Table 2, column C). It is highest in the pygmy squirrel, *Myosciurus pumilio*, and lowest in the insectivorous long-nosed squirrel, *Rhinosciurus laticaudatus*.

The layer of musculature taking origin from the deep surface of the medial aponeurosis of the posterior deep masseter is continuous with the anterior deep masseter and is called the posterior region of that muscle (Ball and Roth, '95). It appears likely that the anterior portion of the anterior deep masseter was derived from this layer in the course of the evolution of sciuromorphy. The extent of this layer varies. It is thin in *Aplodontia* but extends the full length of the zygomatic arch. It is thick and extends to the posterior end of the zygomatic arch in many species of squirrels, as described for *Paraxerus* and *Funisciurus*. This posterior region of the anterior deep masseter is less extensive in other species, e.g., *Sciurus carolinensis*, and is absent in *Paraxerus ochraceus*. It is unclear how extensive this layer of musculature was primitively.

In *Rattus* the anterior deep masseter is an important contributor to the power stroke of both the biting and chewing motions (Weijs and Dantuma, '75). The evolution of sciuromorphy places more fibers of this muscle more anteriorly which serves especially to increase the power of the incisor bite. Squirrels with the most massive anterior deep masseters generally have the most robust incisors and presumably have the strongest incisor bites. *Epixerus*, for example, regularly chews through nuts with a hard husk greater than 10 mm thick (Emmons, '80). More extreme examples of squirrels with powerful anterior deep masseter muscles and unusually stout incisors are *Rheithrosciurus* of Borneo and the fossil *Kubwaxerus* of East Africa (Cifelli et al., '86). Excluding the pygmy squirrel, the highest ratios of lever arm to load arm (Table 2, column C) are found in those squirrels that have the origin of the anterior deep masseter far forward on the premaxillary bone. This correlation suggests that the main functional change is to increase the strength of the incisor bite. In chewing, the anterior deep masseter crosses the occlusal plane of the molars at 60–70°; therefore it contributes significantly to the strength of the bite and also to the protraction of the mandible. The enlargement of the anterior deep masseter in sciuromorphy strengthens this chewing force of the molars.

In pygmy squirrels, the allometry of brain size (Roth and Thorington, '82) forces the reduction of the length of the zygomatic arch, and the area for origin of the posterior deep masseter is greatly reduced. This appears to force the relative emphasis on the anterior deep masseter in these species as exemplified by *Myosciurus*. In this case, the vertical orientation of the fibers is in keeping with an increased importance in chewing.

The posterior deep masseter appears to be quite conservative. The morphology in *Aplodontia* and in modern squirrels differs little in origins or insertions. The muscle does appear to vary in strength. In *Paraxerus* and *Funisciurus* the superficial and medial aponeuroses are relatively weak; the muscle fibers originating from them are long and they insert via a short aponeurosis of insertion, or into the mandible itself. In *Protoxerus*, *Xerus*, and *Ratufa* the aponeuroses of origin and insertion are stronger and more extensive. The aponeurosis of insertion extends dorsally between the superficial and deep aponeuroses of origin and the muscle fibers in-

serting on it are short and numerous, making the muscle more pinnate (Fig. 4).

The posterior deep masseter of squirrels differs little from that in *Rattus*. In *Rattus* the muscle functions during the power strokes of biting and chewing (Weijs and Dantuma, '75). Together with the anterior deep masseter, the temporalis, the zygomaticomandibularis, and the medial pterygoid, it provides the crushing force and the slight forward movement of chewing, while leaving the temporo-mandibular joint unloaded. In *Rattus* propalinal chewing involves the forward movement of the mandible under the maxilla for 2–3 mm. In squirrels the horizontal space between the upper and lower incisors is sufficient to allow approximately the same amount of movement. During incisor biting the lever arm measured for posterior deep masseter (Table 2, columns A and B) is shorter than that of the anterior deep masseter (Table 2, C) and the same as that of the superficial masseter (Table 2, columns A and B). However, the fibers of the superficial masseter and of the anterior deep masseter are more nearly perpendicular to the lever arm, whereas the fibers of the posterior deep masseter lie at an acute angle to the line of measurement of the lever arm (Fig. 2). Therefore, the mechanical advantage of the posterior deep masseter is even less, and the muscle will add less to the power stroke of the incisor bite.

If the primitive insertion of the anterior deep masseter was limited to the ventral masseteric ridge of the mandible, as we posit, then it is probable that the primitive insertion of the anterior portion of the zygomaticomandibularis extended the length of the dorsal masseteric ridge. As noted before, it is impossible to verify this in the fossil record because the insertions of the two muscles are not distinguishable on the bone. The extensive musculous insertion of the anterior portion of the zygomaticomandibularis in most squirrels is similar to that in *Aplodontia*. The reduced insertion in *Callosciurus* and *Tamiops* is a derived condition. Another derived condition is the posterior displacement of the insertion of the zygomaticomandibularis by the insertion of the anterior deep masseter on the dorsal masseteric ridge. This condition is seen in *Protoxerus*, *Funambulus*, and *Sciurus*. The area of insertion of the posterior portion of the zygomaticomandibularis is a distinctly visible fossa on the condyloid process and can be seen in *Palaosciurus*

goti, of the Oligocene, as illustrated by Vianey-Liaud ('74). This fossa of insertion varies only slightly in size and depth among the squirrels we have examined.

The zygomaticomandibularis was not included in the study of function of jaw muscles in *Rattus* by Weijs and Dantuma ('75). The primarily vertical orientation of the anterior fibers of this muscle suggests that they are used in the power stroke of chewing but, judging from its small size, the zygomaticomandibularis is not a strong muscle. Because the most anterior fibers of the zygomaticomandibularis are differently oriented from fibers of the anterior deep masseter, the changes in their covarying insertions will have some functional significance.

Variation in the temporalis musculature is evident from variation in the size of the coronoid process on which it inserts. The coronoid process is diminished, independently, in three genera of Old World squirrels, *Xerus*, *Funambulus*, and *Myosciurus* (Fig. 3a,b). In *Xerus* and *Funambulus* the reduction of the coronoid process is accompanied by a decrease in the thickness of the most ventral and posterior portions of the medial temporalis. The lateral temporalis and the anterior portion of the medial temporalis, however, with vertically oriented fibers that insert posterior to the third molar at the base of the coronoid process, are not reduced in size compared with squirrels that have a larger coronoid process. In *Rattus* the temporalis is one of the muscles that functions in propalinal chewing (Weijs and Dantuma, '75). The most posterior fibers assist in the retraction of the mandible in the recovery stroke of chewing. The more anterior fibers have a primarily vertical component and function strongly during the power stroke of chewing. This suggests that for *Xerus* and *Funambulus*, the role of the temporalis muscle in the power strokes of chewing and biting is not lessened, but that its role in retracting the mandible is. In *Myosciurus* the anterior, vertically oriented fibers of the temporalis musculature are absent and only a portion of the medial temporalis is retained. These fibers have a mostly horizontal orientation. This arrangement suggests that the muscle's role in retracting the mandible is retained but its role in biting and chewing is not. During the power stroke of biting in all squirrels, the temporalis functions with a shorter lever arm and less mechanical advantage than the anterior deep masseter and most of the fibers of

the superficial masseter (Table 2, columns D and E).

The medial pterygoid muscle varies little among the genera we studied. It functions to close the jaw and is probably most important as one of the sling muscles involved in molar chewing. Because of the orientation of the fibers, it has a much shorter lever arm than the anterior deep masseter and is therefore relatively less important in the incisor bite.

The lateral pterygoid muscle is the only muscle positioned so that it will protract the mandible without adducting it. It probably serves to protract the mandible in preparation for the incisor bite. It varies little in the genera we studied.

The submandibular musculature also does not vary significantly among these squirrels. The digastric functions to retract and lower the mandible. The intermandibularis functions both to pull the mandibular rami toward one another and to assist in the independent movement of the two rami. The other submandibular muscles are important in movements of the hyoid and tongue (Hiimae and Crompton, '85).

Moore ('59) placed the Indian striped squirrels, *Funambulus*, in the same tribe with the African *Paraxerus*, *Funisciurus*, and *Myosciurus*, on the basis of two shared morphological characters. One of these is the presence of one to two bony septa in the auditory bulla, which is probably primitive for squirrels (Thorington et al., 1996b). Several tribes of squirrels have one to two septa (Moore, '59), therefore this is an unreliable character for determining relationships. The second character involves the juxtaposition of the premaxillary and nasal bones, but this is not identical in *Funambulus* and the African squirrels. We have found that the jaw musculature of *Paraxerus* and *Funisciurus* is the most primitive among recent squirrels, whereas *Funambulus* exhibits one of the most derived stages of sciuromorphy, with major differences from the African squirrels in both the masseter and temporalis musculature. Consequently, the evidence is weak for including *Funambulus* in the same tribe with the African genera *Paraxerus*, *Funisciurus*, and *Myosciurus*.

The ecological context for the evolution of sciuromorphy is difficult to evaluate, because the adaptation may have arisen as early as the Miocene in the ancestry of the squirrels we have studied. Our expectation was that derived sciuromorphy would be associated

with feeding on hard fruits. This is true for three genera: *Sciurus*, which feeds commonly on *Carya*, the hickorys; *Protoxerus*, which feeds on the hard-shelled nuts of *Panda oleosa* (Emmons, '80); and *Ratufa*, which feeds on hard fruits of species such as Teak, *Tectona grandis* (Thorington and Cifelli, '90). In three other genera there is no documented association with feeding on hard fruits. *Funambulus* is known to feed on a variety of soft fruits and seems to actively avoid hard seeds (Balasubramanian, '95). The feeding preferences of *Callosciurus* do not include an emphasis on hard fruits, although some, like *Lithocarpus*, are included in the diet (Payne, '80). *Xerus* also is not known for feeding on hard fruits (Herzig-Straschil, '78; Herzig-Straschil and Herzig, '89). The hardest fruit utilized is that of the Baobab tree, *Adantonia digitata*, fed on by one species, *Xerus rutilus* (O'Shea, '91). Therefore, this behavior is not closely associated among recent squirrels with the derived sciuriform morphology.

CONCLUSIONS

The jaw musculature of Old World squirrels varies more than that of New World squirrels, exhibiting both more primitive and more derived morphologies. The African squirrels *Paraxerus* and *Funisciurus* have a more primitive form of sciuriformity than other squirrels. The giant squirrels of Southeast Asia, *Ratufa*, have a uniquely derived masseter morphology. The African pygmy squirrel, *Myosciurus*, is similar to the South American pygmy squirrel, *Sciurillus*, and probably is also similar to the unstudied Asian pygmy squirrels. Other derived morphologies of sciuriformity have evolved independently numerous times among the tribes of Sciuridae.

ACKNOWLEDGMENTS

This study was motivated by our reading the manuscript of Steven Ball and Louise Roth, and we thank Louise for her continuing interest and encouragement. We thank Lawrence Heaney and William Stanley for loan of specimens from the Field Museum, and Duane Schlitter and Susan McLaren for a loan from the Carnegie Museum. Dan H. Nicolson and Dieter Wasshausen assisted us with botanical evaluation of the literature on squirrel diets. We also profited from the comments and suggestions of our two reviewers.

LITERATURE CITED

- Balasubramanian, P. (1995) Some notes on the fruits, seeds and nectar consumed by three striped palm squirrels, *Funambulus palmarum*, at Point Calimere Wildlife Sanctuary, Tamil Nadu. *J. Bombay Nat. Hist. Soc.* 92:256-258.
- Ball, S.S., and V.L. Roth (1995) Jaw muscles of New World squirrels. *J. Morphol.* 224:265-291.
- Black, C.C. (1963) A review of the North American tertiary Sciuridae. *Bull. M.C.Z.* 130:113-248.
- Brandt, J.F. (1855) Beiträge zur nähern Kenntniss der Säugethiere Russlands. *Mem. Acad. Imp. Sci. St.-Petersbourg*, ser. 6, vol. 9.
- Bryant, M.D. (1945) Phylogeny of Nearctic Sciuridae. *Am. Midland Nat.* 33:257-390.
- Cifelli, R.L., A.K. Ibuti, L.L. Jacobs, and R.W. Thorington, Jr. (1986) A giant tree squirrel from the late Miocene of Kenya. *J. Mamm.* 67:274-283.
- Emmons, L.H. (1980) Ecology and resource partitioning among nine species of African rain forest squirrels. *Ecol. Monogr.* 50:31-54.
- Emry, R., and W.W. Korth (1996) A new genus of squirrel (Sciuridae: Rodentia) from the Chadronian of western North America. *J. Vert. Paleo.* (in press).
- Emry, R., and R.W. Thorington, Jr. (1982) Descriptive and comparative osteology of the oldest fossil squirrel, *Protosciurus* (Rodentia: Sciuridae). *Smithson. Contrib. Paleobiol.* 47:1-35.
- Herzig-Straschil, B. (1978) On the biology of *Xerus inauris* (Zimmerman, 1780) (Rodentia, Sciuridae). *Z. Säugetierkunde* 43:262-278.
- Herzig-Straschil, B., and A. Herzig (1989) Biology of *Xerus princeps* (Rodentia, Sciuridae). *Madoqua* 16:41-46.
- Hiimae, K. (1971a) The structure and function of the jaw muscles in the rat (*Rattus norvegicus* L.). I. Their anatomy and internal architecture. *Zool. J. Linn. Soc.* 50:75-99.
- Hiimae, K. (1971b) The structure and function of the jaw muscles in the rat (*Rattus norvegicus* L.). III. The mechanics of the muscles. *Zool. J. Linn. Soc.* 50:111-132.
- Hiimae, K., and A.W. Crompton (1985) Mastication, food transport, and swallowing. In M. Hildebrand, D.M. Bramble, K.F. Liem, and D.B. Wake (eds): *Functional Vertebrate Morphology*. Cambridge, MA: Harvard University Press, pp. 262-290.
- Hill, J.E. (1937) Morphology of the pocket gopher, mammalian genus *Thomomys*. *Univ. Calif. Publ. Zool.* 42:81-172.
- Korth, W.W. (1987) Sciurid rodents (Mammalia) from the Chadronian and Orellan (Oligocene) of Nebraska. *J. Paleontol.* 61:1247-1255.
- Moore, J.C. (1959) Relationships among living squirrels of the Sciurinae. *Bull. Am. Mus. Nat. Hist.* 118:153-206.
- Nomina Anatomica (1966) Prepared by the International Anatomical Nomenclature Committee. New York: Excerpta Medica Foundation. 112 pp.
- O'Shea, T.J. (1991) *Xerus rutilus*. *Mammalian Species*. *Am. Soc. Mamm.* 370:1-5.
- Parsons, F.G. (1894) On the myology of the sciuriform and hystricomorphine rodents. *Proc. Zool. Soc.* 18:251-297.
- Payne, J.B. (1980) Competitors. In D.J. Chivers (ed): *Malayan Forest Primates*. New York: Plenum Press, pp. 261-278.
- Roth, V.L., and R.W. Thorington, Jr. (1982) Relative brain size among African squirrels. *J. Mamm.* 63:168-173.

- Schaller, O. (1992) Illustrated Veterinary Anatomical Nomenclature. Germany: Ferdinand Enke Verlag Stuttgart, 614 pp.
- Simpson, G.G. (1945) The principles of classification and a classification of mammals. *Bull. Am. Mus. Nat. Hist.* 85:1-350.
- Thorington, R.W., Jr., and R.L. Cifelli (1990) The unusual significance of the Giant Squirrels (*Ratufa*). In J.C. Daniel and J.S. Serrao (eds): Conservation in Developing Countries: Problems and Prospects. Proceedings of the Centenary Seminar of the Bombay Natural History Society. Bombay: Oxford University Press, 656 pp.
- Thorington, R.W., Jr., A.L. Musante, C.G. Anderson, and K. Darrow (1996a) Validity of three genera of flying squirrels: *Eoglaucmys*, *Glaucmys*, and *Hyloteles*. *J. Mamm.* 77:69-83.
- Thorington, R.W., Jr., A.L. Musante, and C.G. Anderson (1996b) Arboreality in tree squirrels (Sciuridae). In M.A. Steele, J.F. Merritt, and D.A. Zegers (eds): Ecology of Tree Squirrels. Special Publication, Carnegie Museum of Natural History (in press).
- Toldt, C. (1905) Der Winkelforsatz des Unterkiefers beim Menschen und bei den Säugetieren und die Beziehungen der Kaumuskel zu Denselben, II Teil. *Sitz. Kais. Akad. Wiss. Wien Math. Naturwiss. Kl.* 114:315-476.
- Tullberg, T. (1899) Ueber das System der Nagethiere: eine phylogenetische studie. Uppsala: Akad. Buchdruckerei, v + 514 pp., 57 pls.
- Turnbull, W.D. (1970) Mammalian masticatory apparatus. *Fieldiana Geol.* 18:149-356.
- Vianey-Liaud, M. (1974) *Palaeosciurus goti* nov. sp., Ecureuil terrestre de L'Oligocène moyen du quercy. Données nouvelles sur l'apparition des sciuridés en Europe. *Ann. Paléontol. (Vertebr.)* 60:103-122.
- Weijs, W.A., and R. Dantuma (1975) Electromyography and mechanics of mastication in the albino rat. *J. Morphol.* 146:1-34.

APPENDIX

Aplodonta rufa: USNM 218729

Atlantoxerus getulus: USNM 477054
Callosciurus flavimanus: USNM 579897
Callosciurus notatus: USNM 521151, 84702, 86338
Funambulus palmarum: USNM 448821
Funisciurus anerythrus: USNM 463536
Funisciurus lemniscatus: USNM 539418
Heliosciurus rufobrachium: USNM 463538, 463544, 463545, 541537
Heliosciurus gambianus: USNM 381419, 481830
Myosciurus pumilio: USNM 514360
Nannosciurus melanotis: USNM 199007
Paraxerus palliatus: USNM 548034
Paraxerus ochraceus: USNM 251930
Protoxerus stangeri: USNM 481821, 481817
Ratufa bicolor: USNM 546334
Ratufa indica: USNM 548661
Sciurus carolinensis: USNM 396002, 497249, 497250, 522976
Tamiops maclellandi: FMNH 37915, 37906
Xerus erythropus: USNM 481845
Xerus rutilus: CM 86231
